
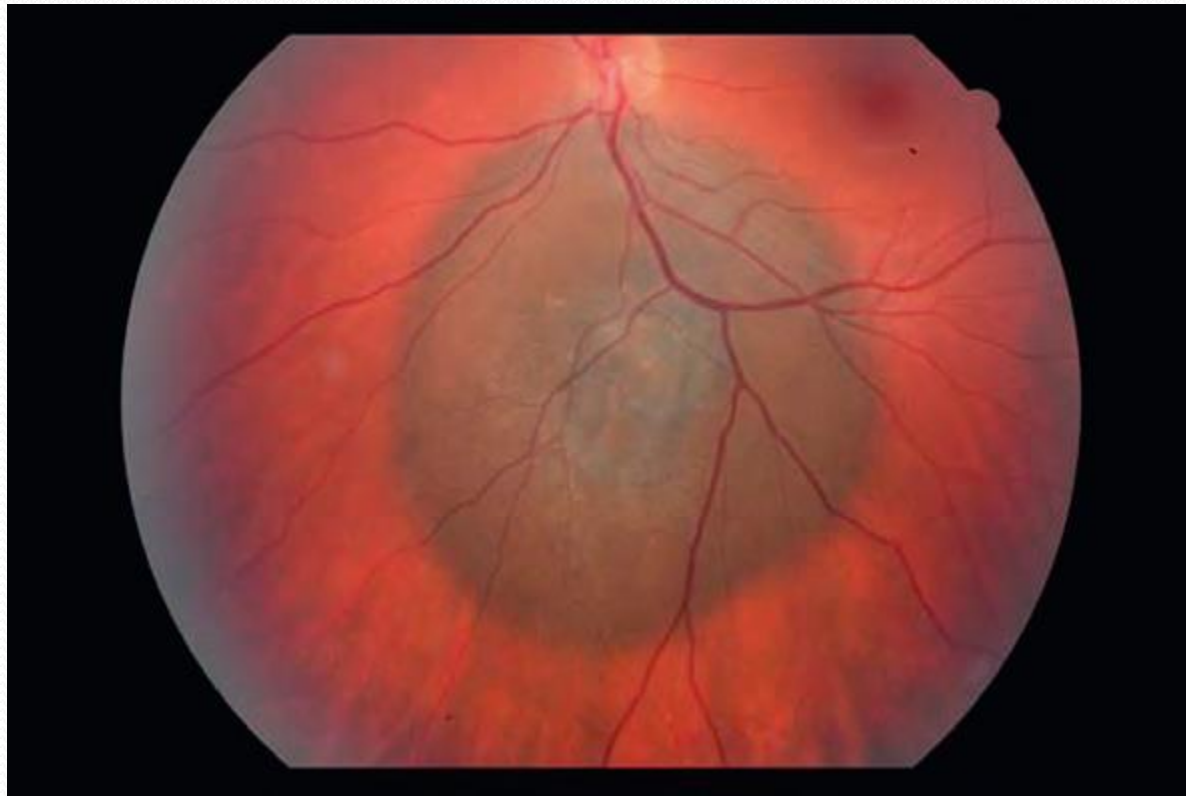
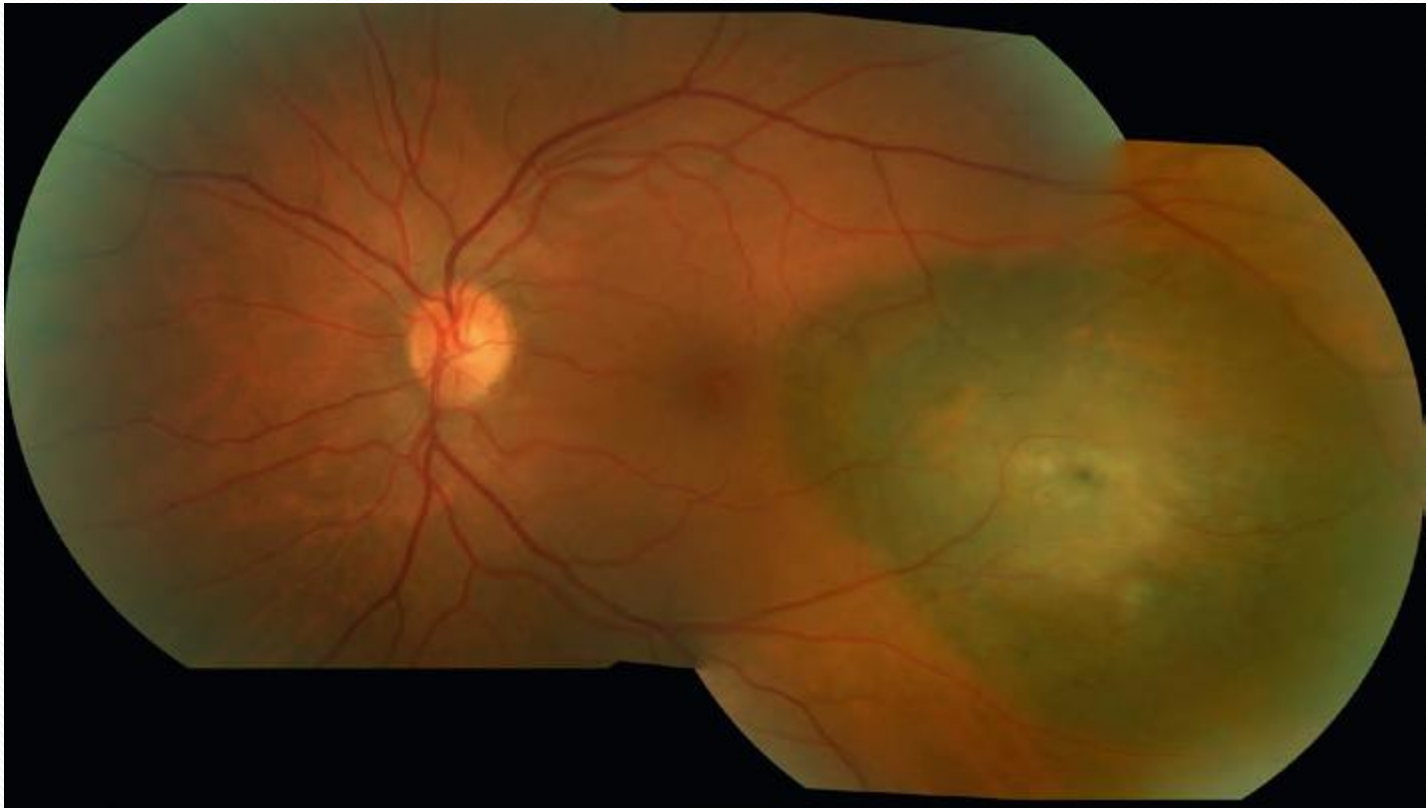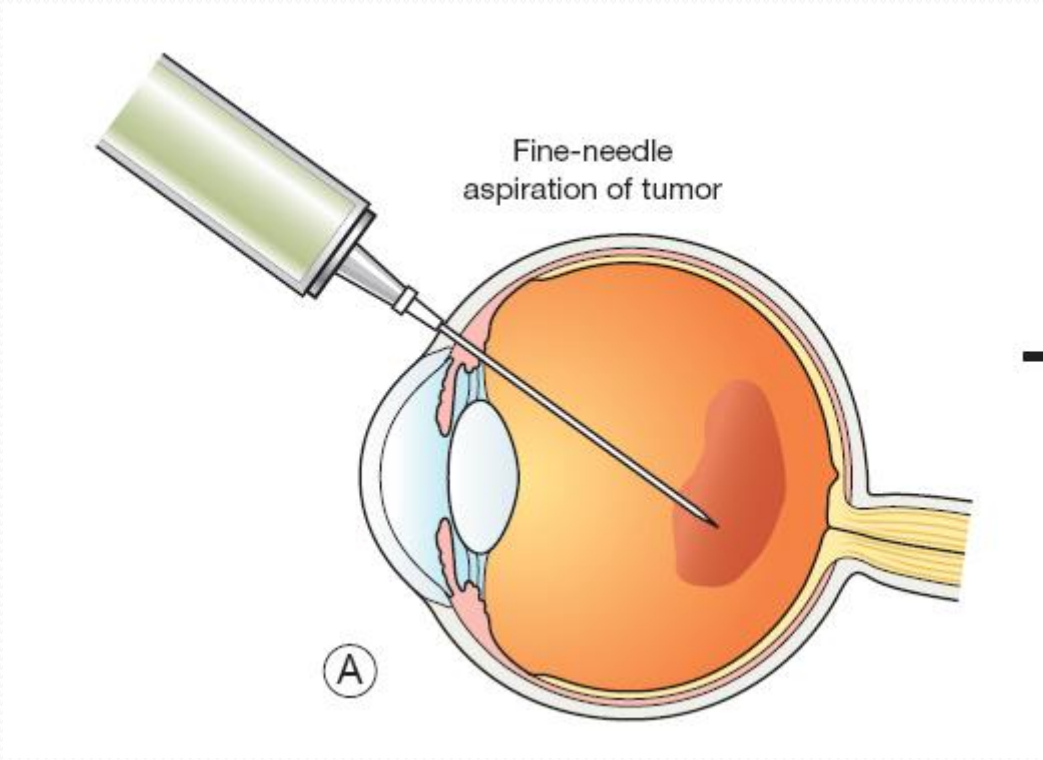
Intraocular tumors

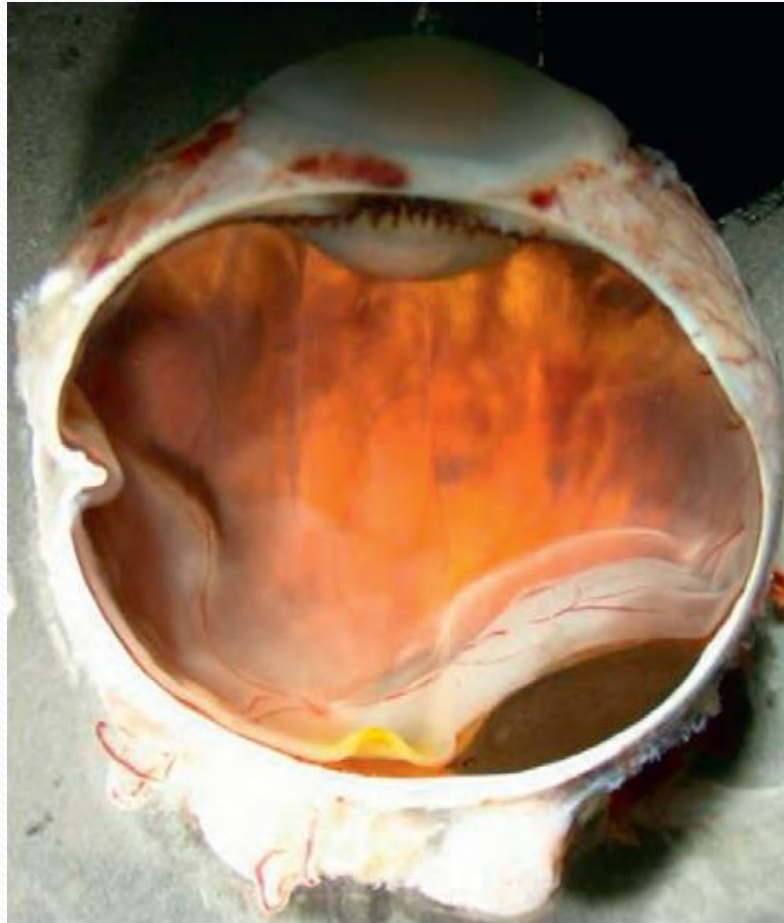Saeed Karimi MD

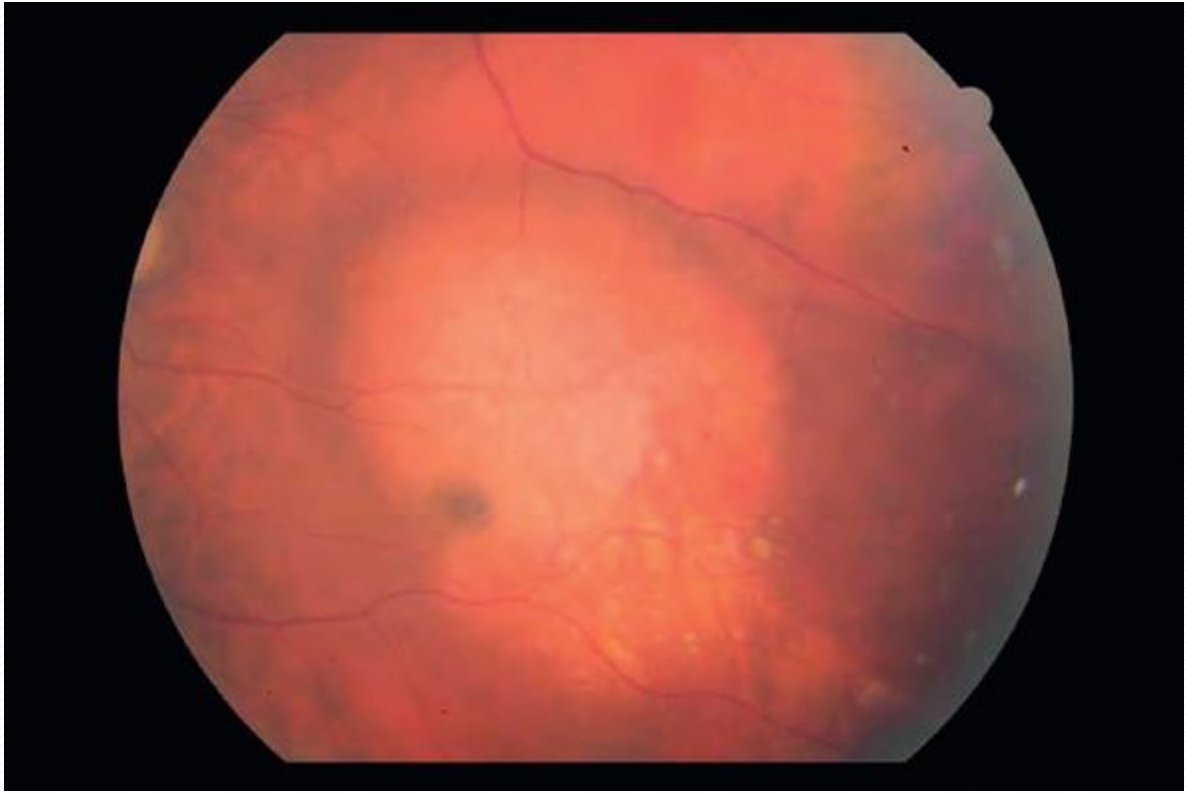
- 
- A 65 y/o man
 - Deceased VA since 2 months ago

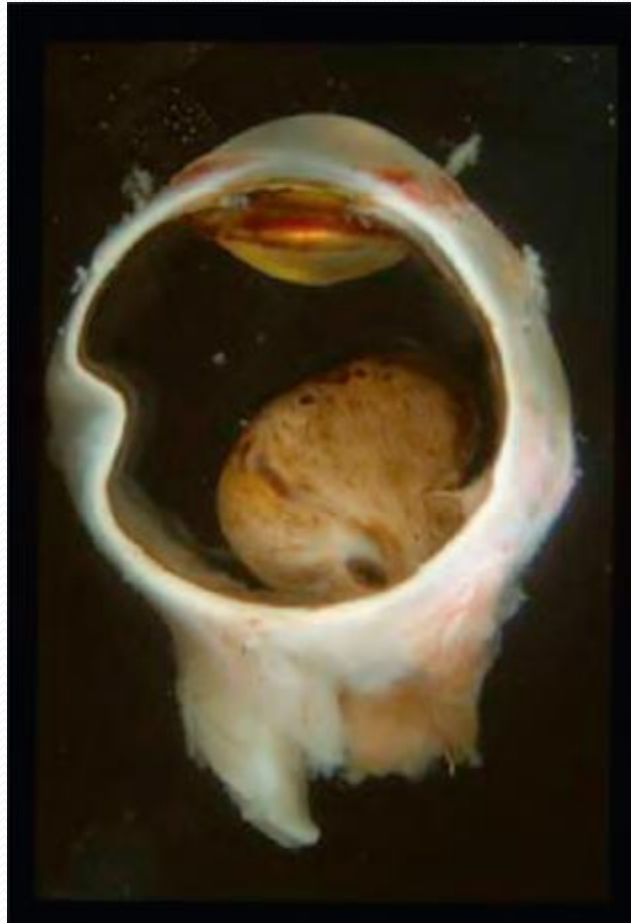


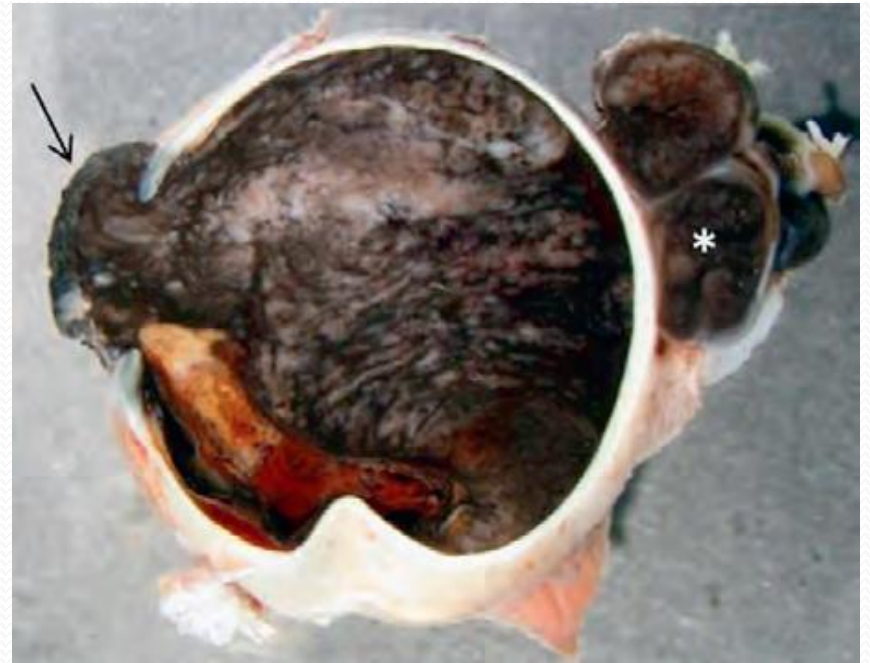
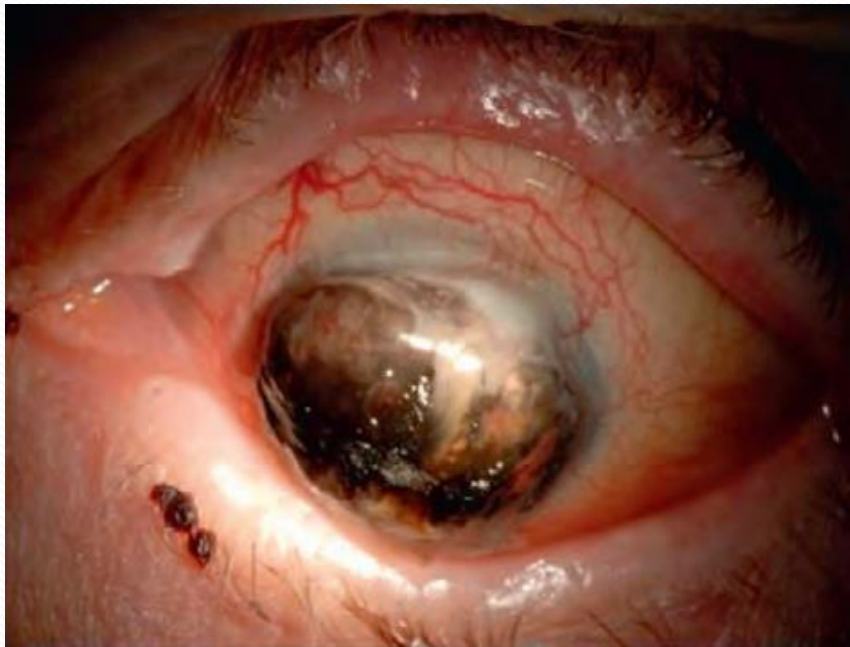
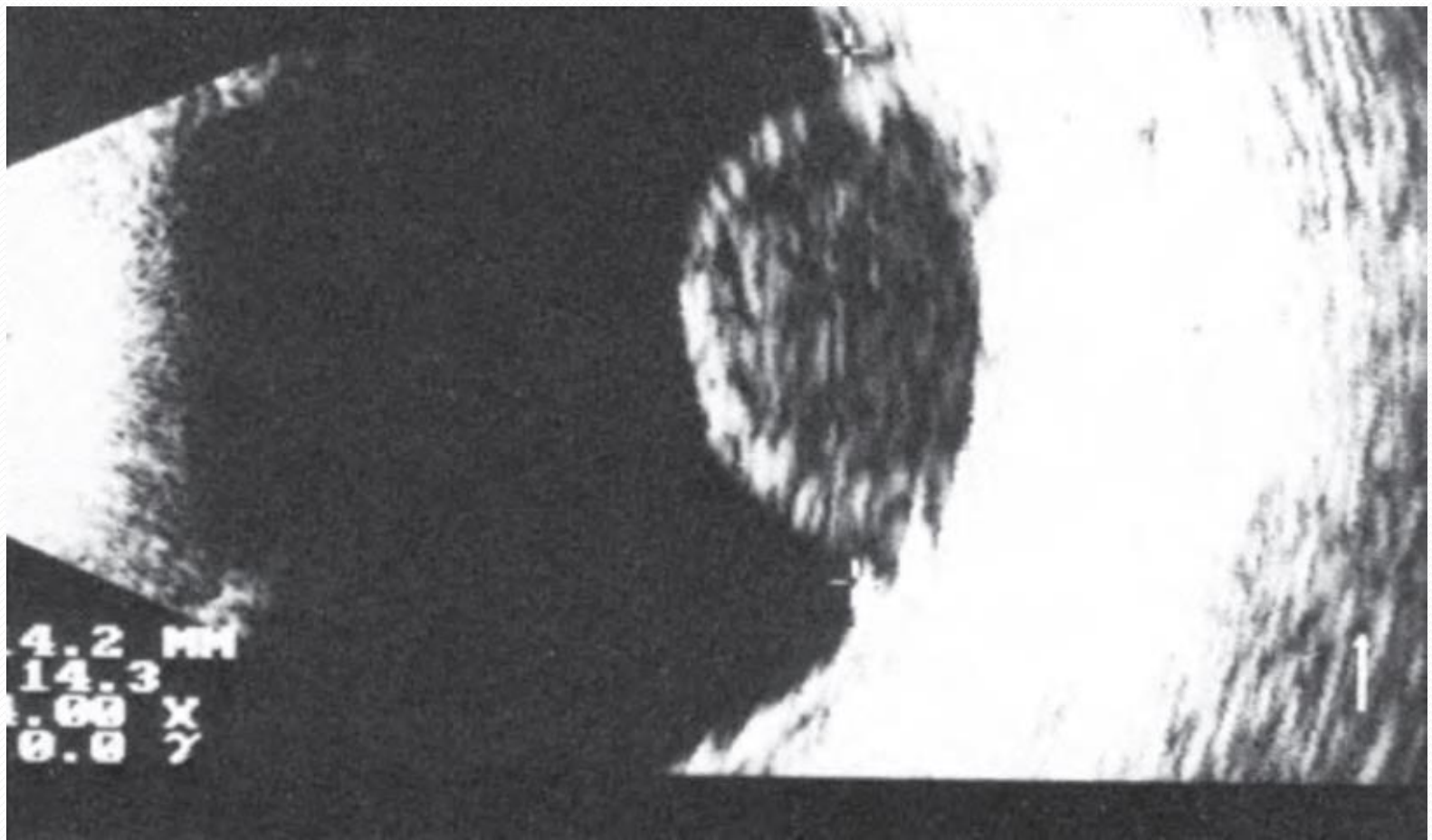


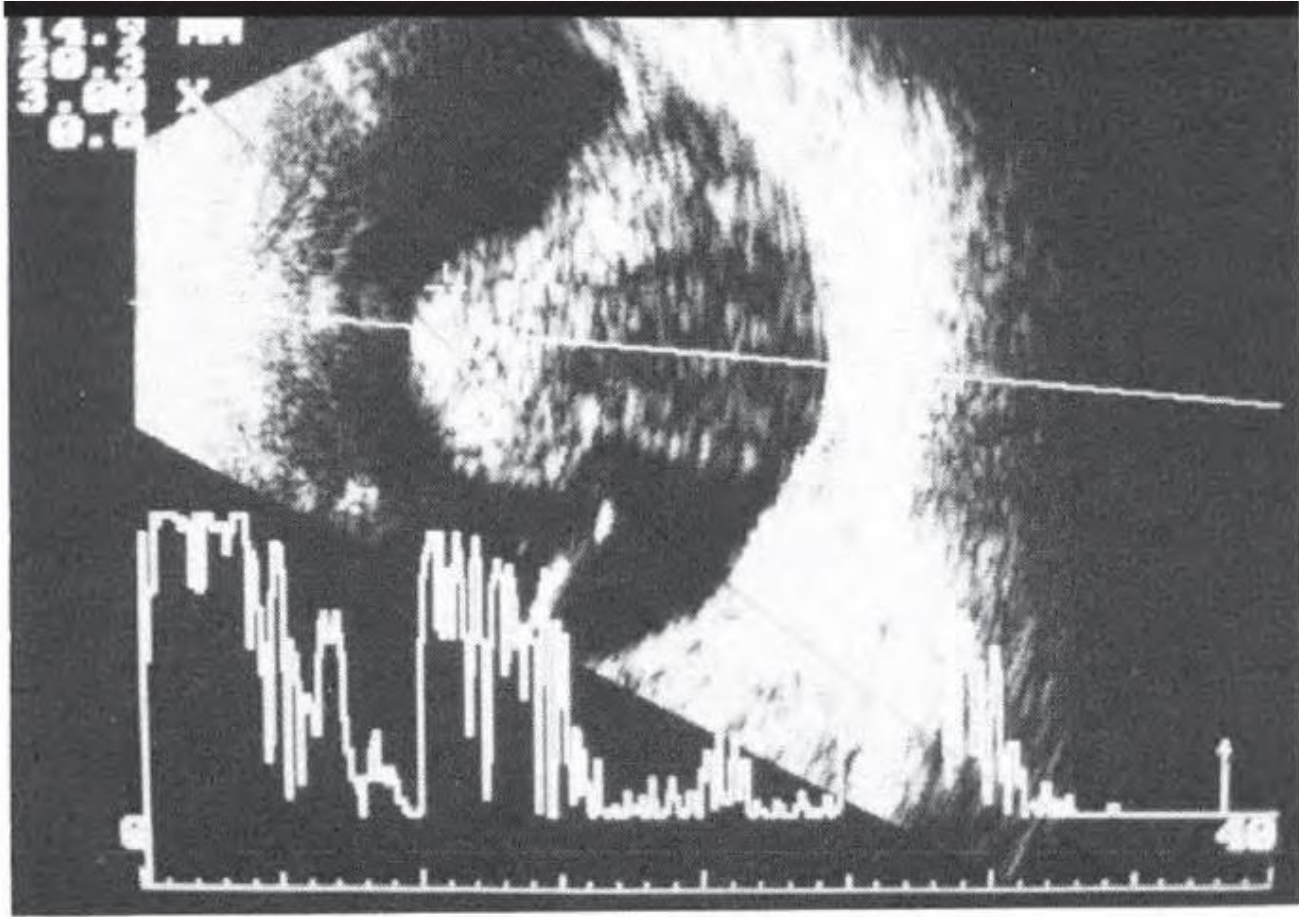




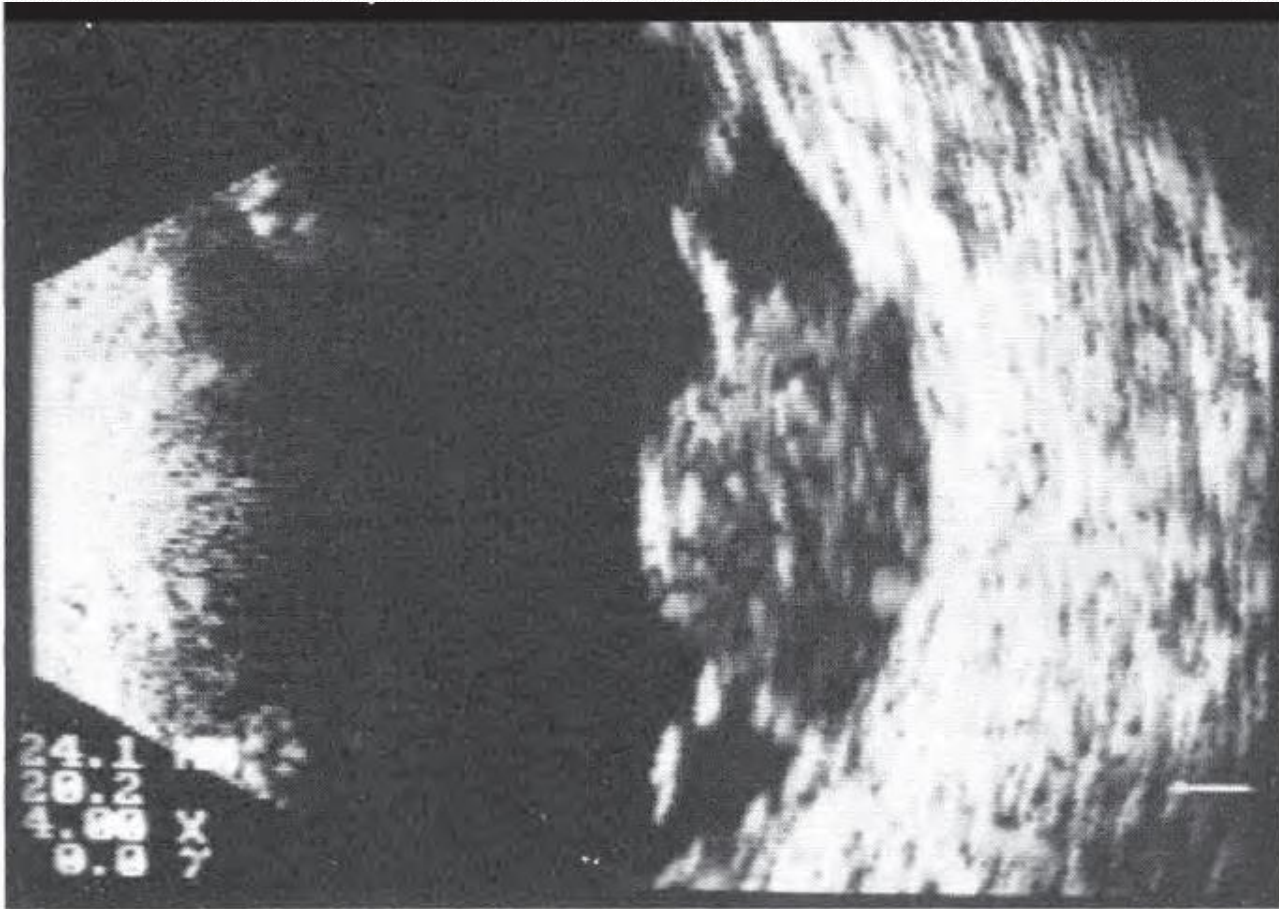

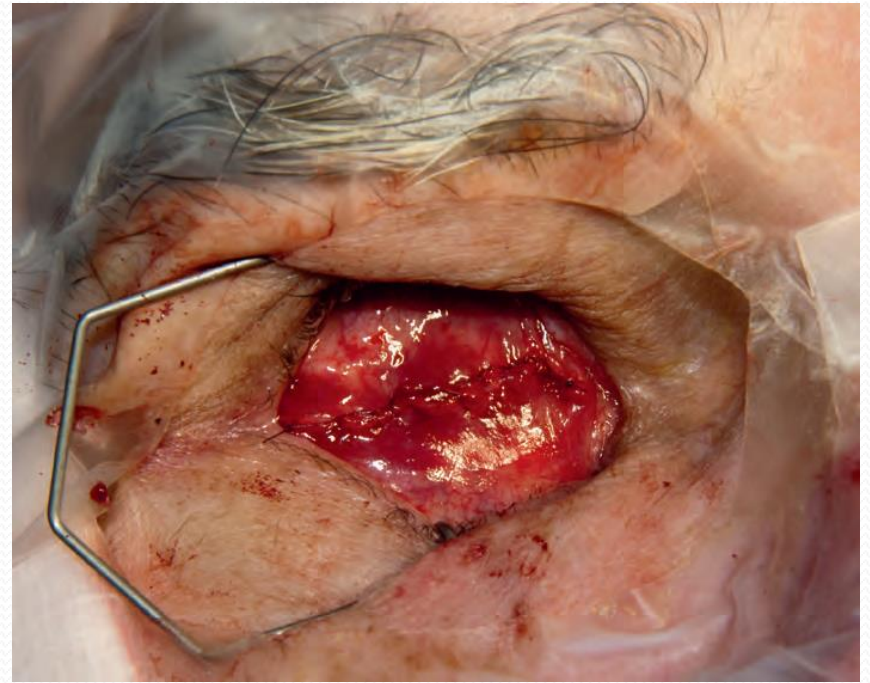
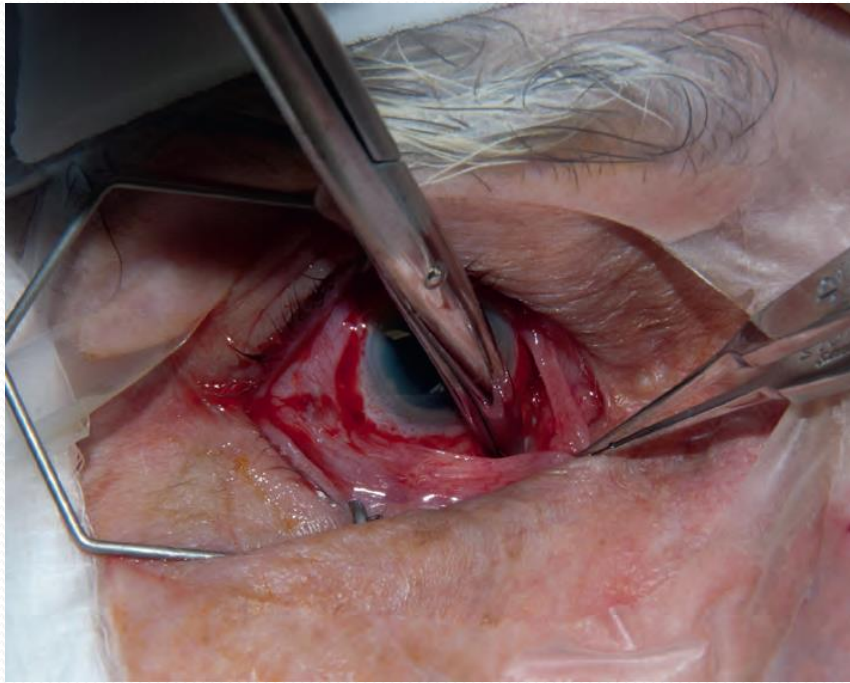




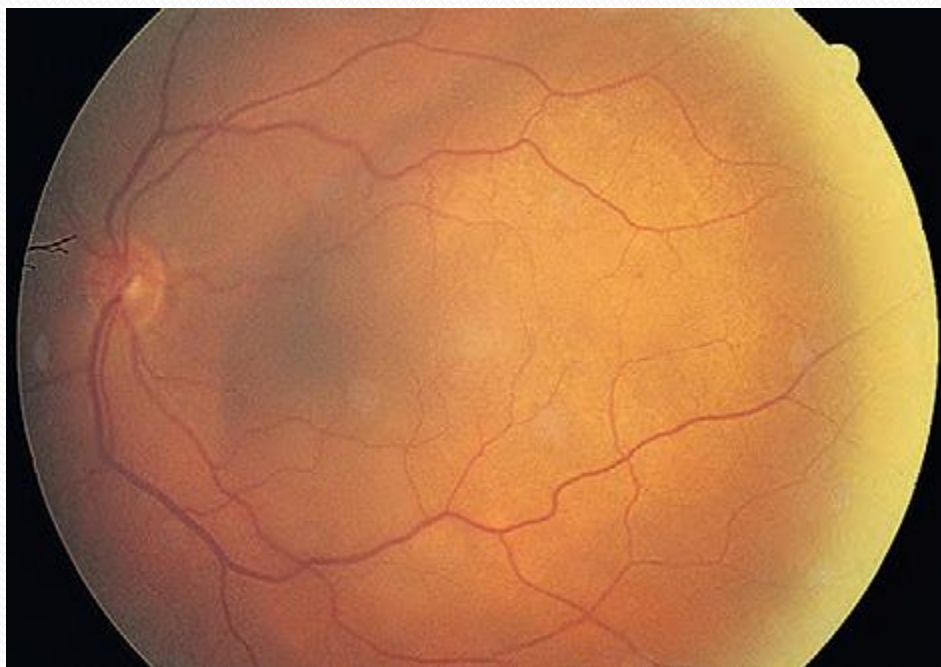


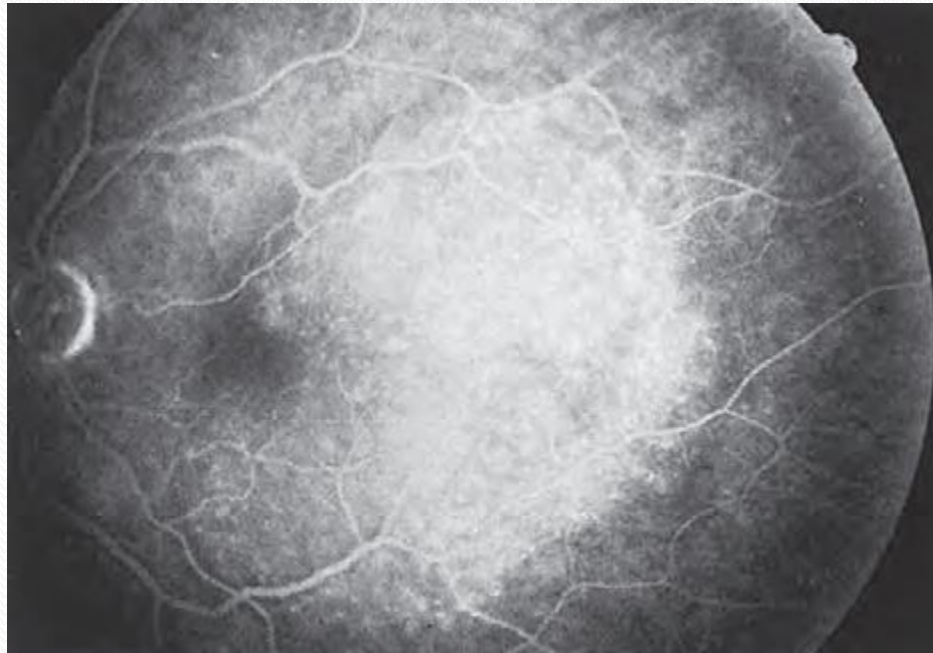


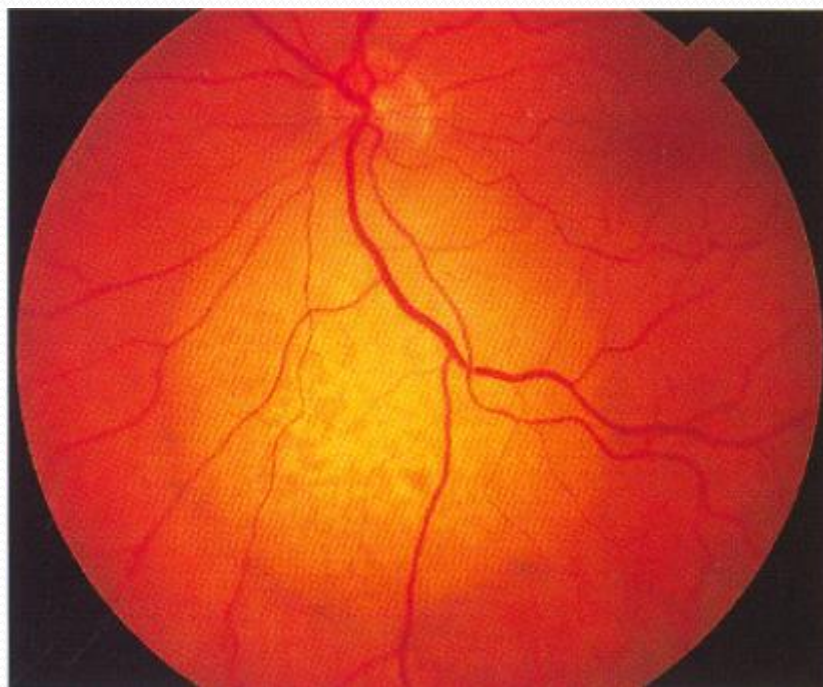
- 
- Metastatic work up

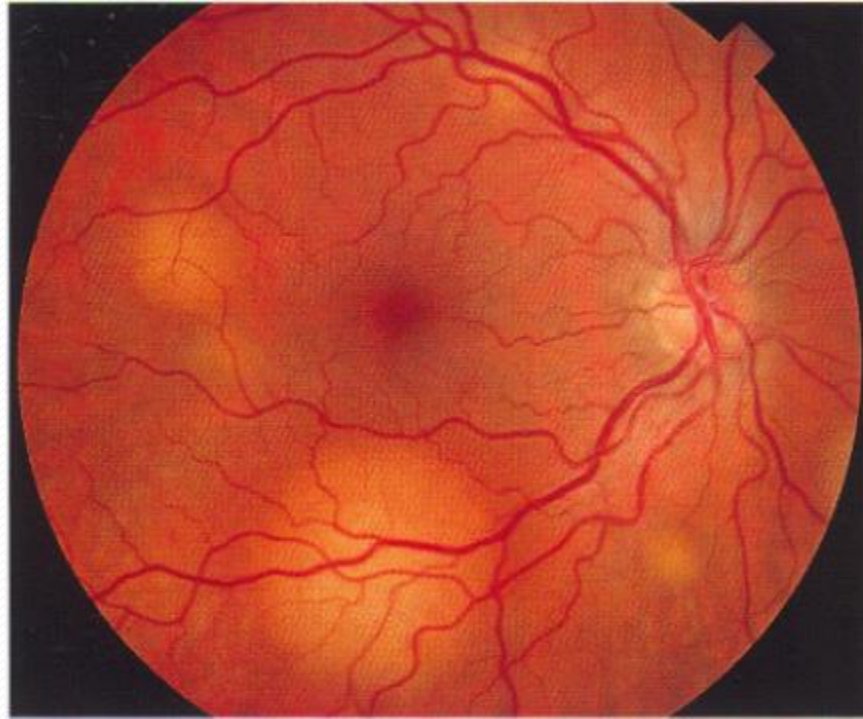


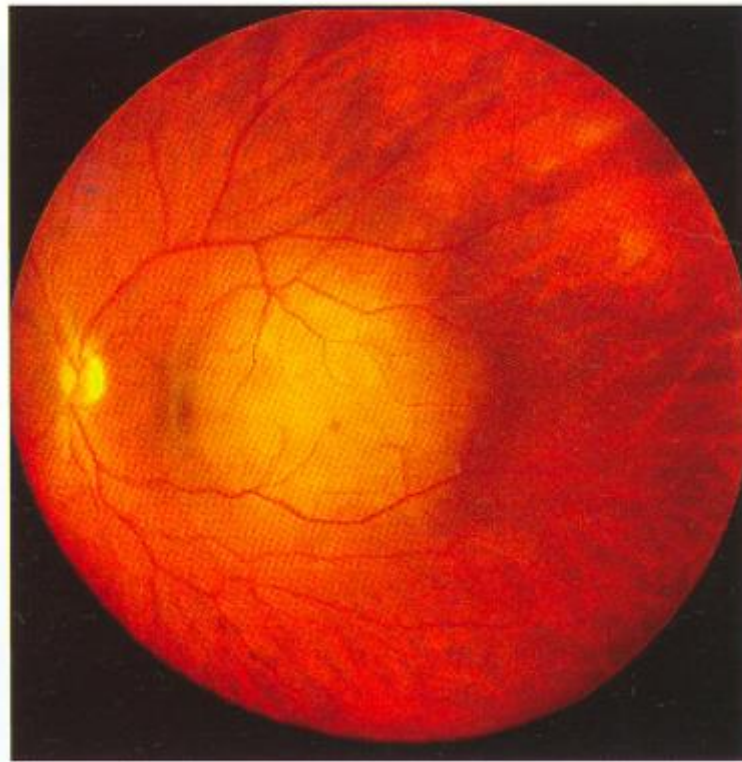
- 
- A 55 y/o female
 - Decreased VA since one month ago



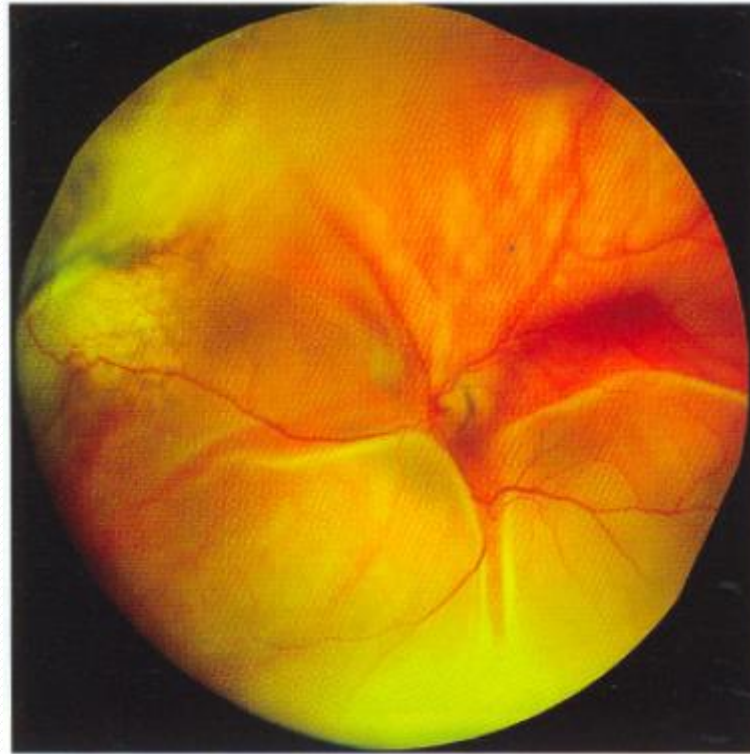




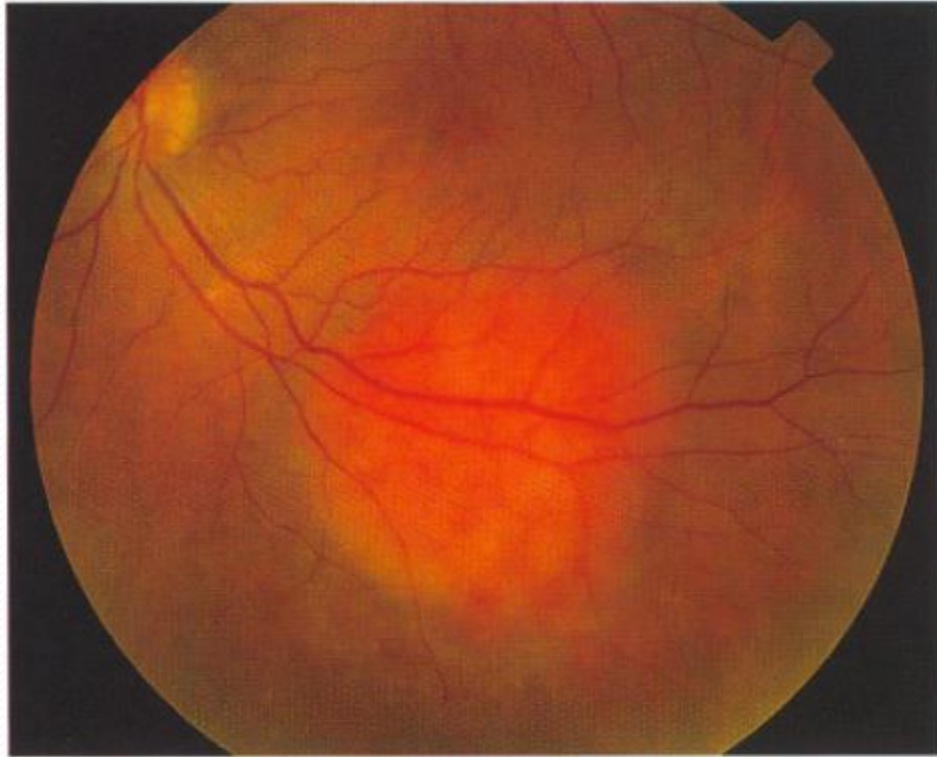


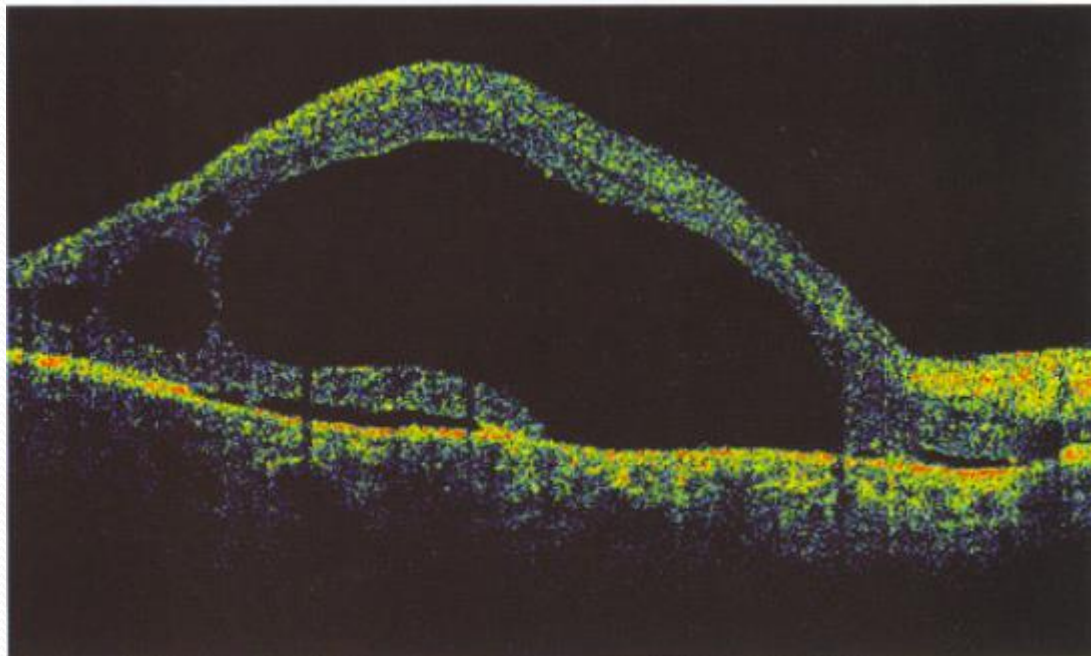


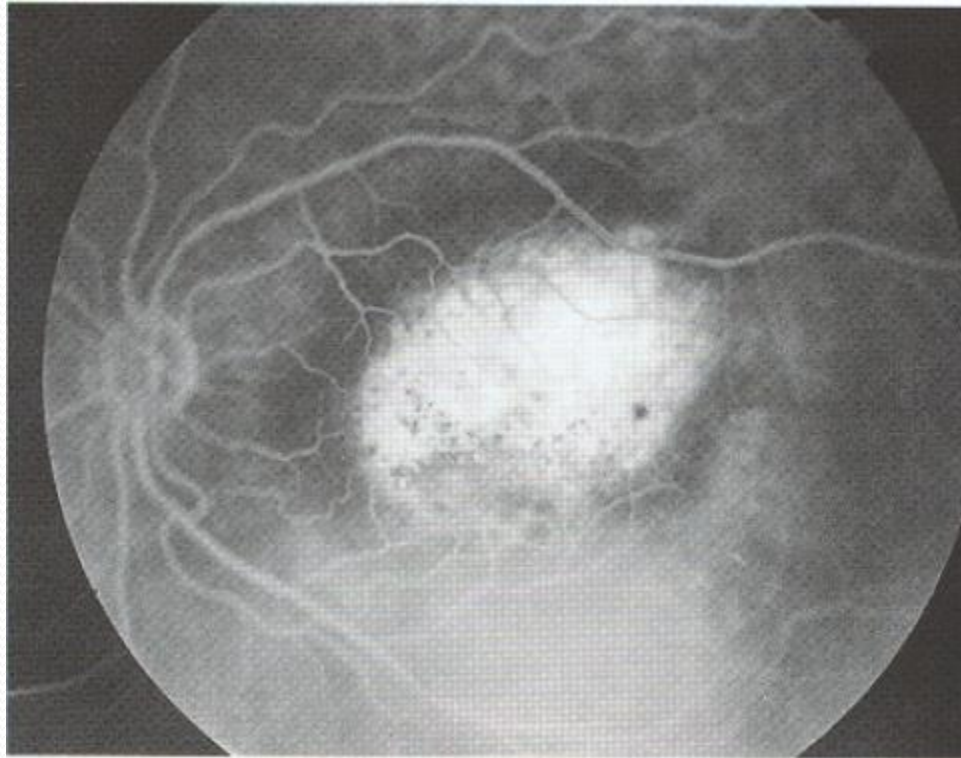
.38. Macular choroidal metastasis from lung cancer.



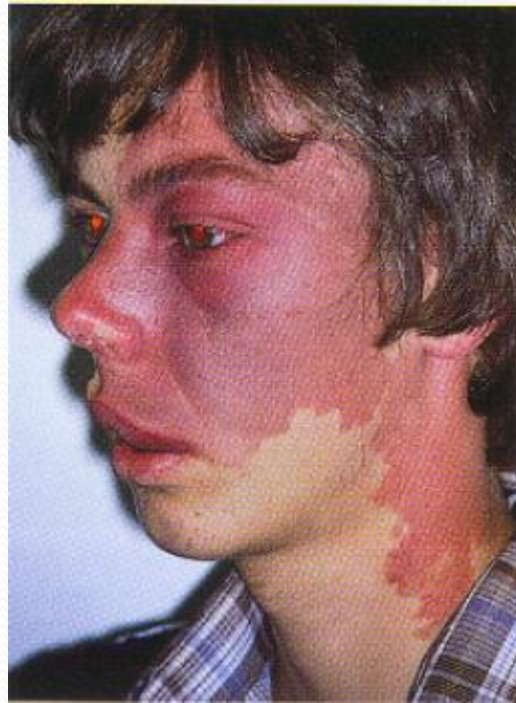Circumscribed Choroidal Hemangioma:

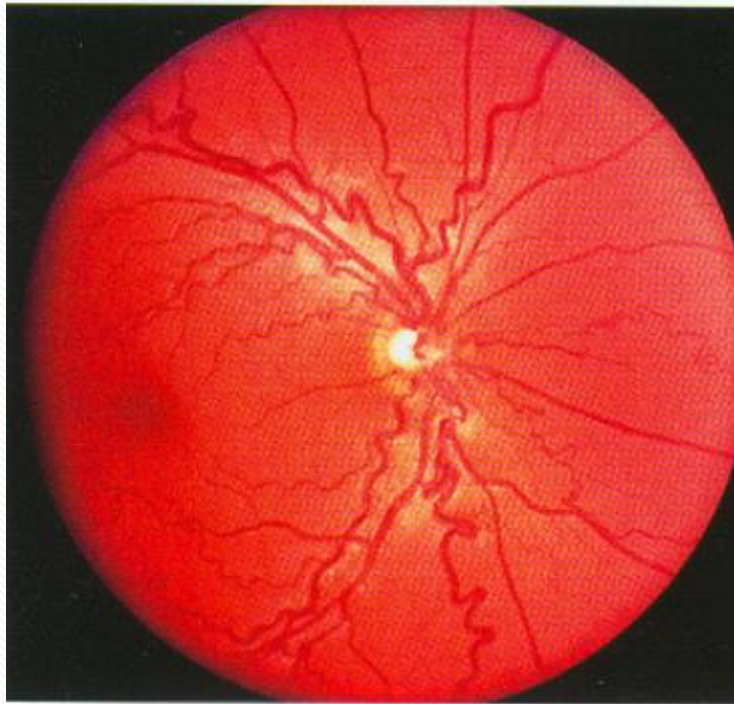




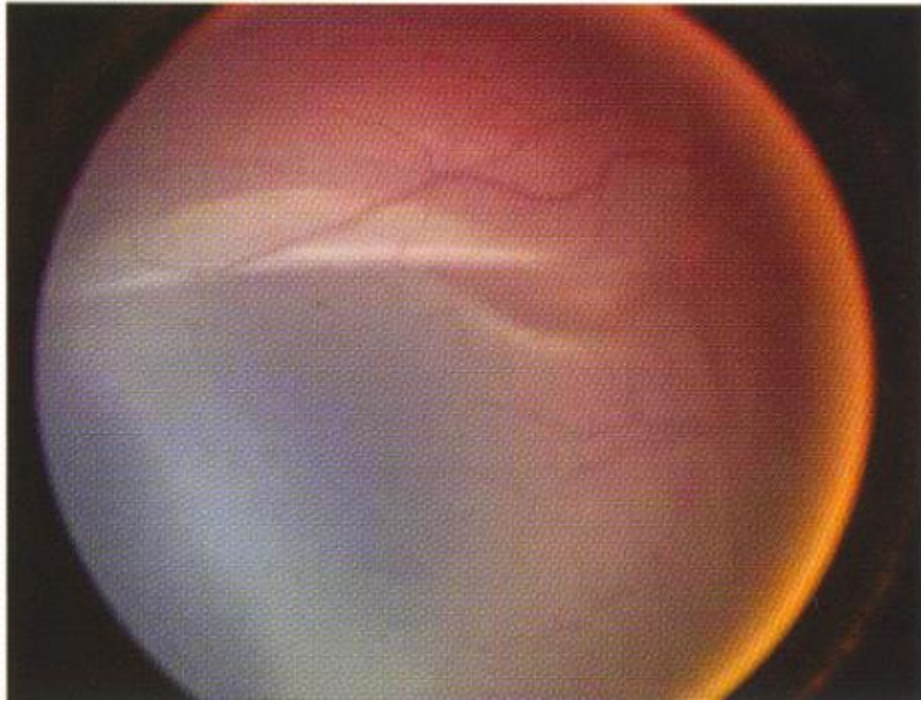



Diffuse Choroidal Hemangioma: Sturge-Weber Syndrome



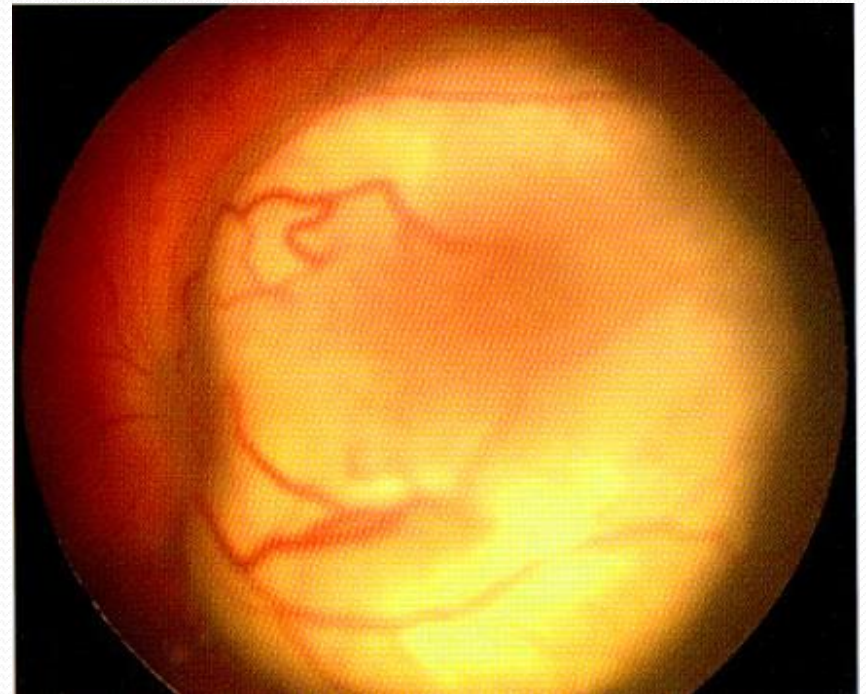
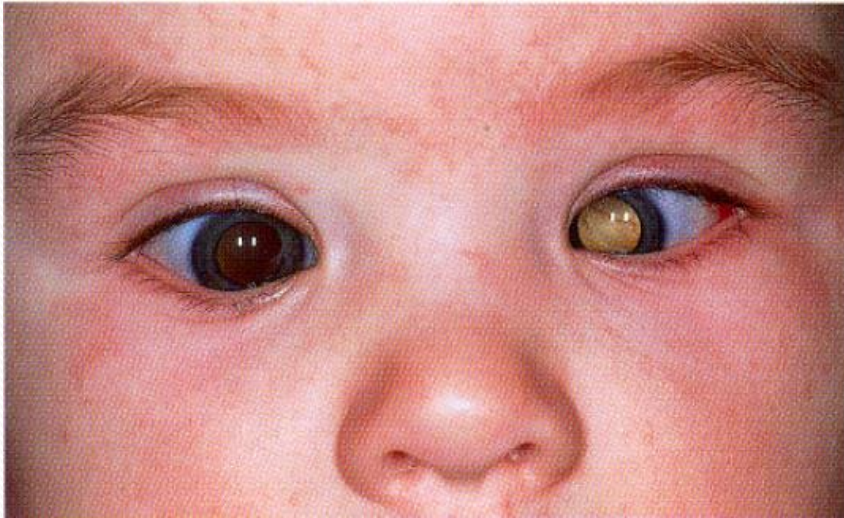

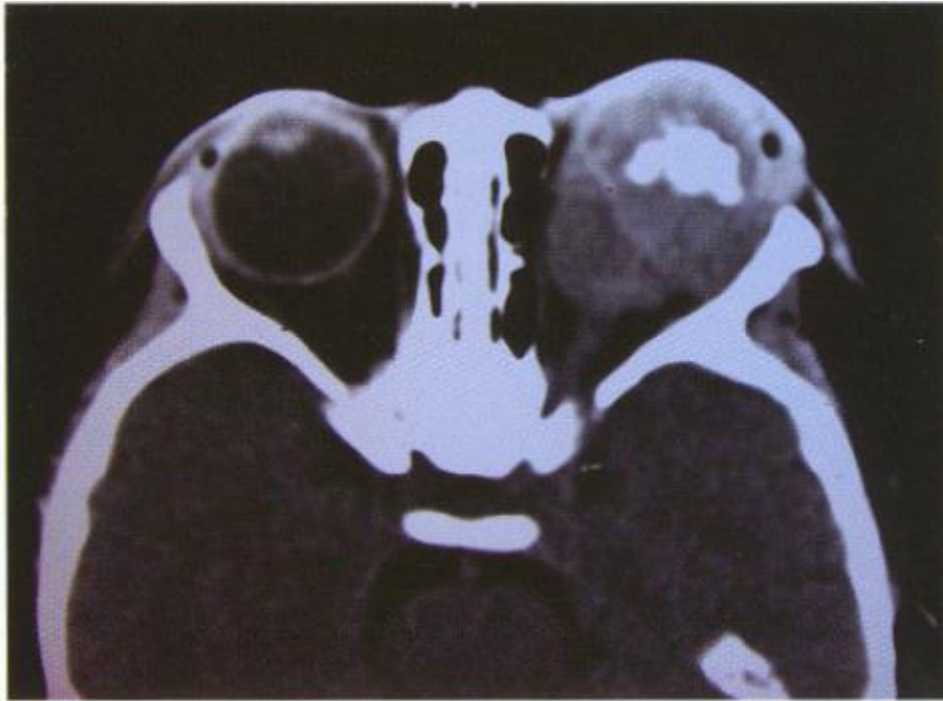37. Appearance of the "tomato catsup" fundus s



- 
- A 1.5 y/o boy
 - Leukocoria

Retinoblastoma





Hemangioblastoma

